

**PATIENT**

Keanu Marrcotte

**PRESENTING CLINICAL SIGNS**

Heart murmur, considering dentistry

Abnormal PE/Chem/CBC/UA Results: prev US report attached.

**SPECIES**

Feline

**ULTRASONOGRAPHIC EXAMINATION OF THE HEART**

**BREED**

DSH

**SEX**

MN

**AGE**

8yr

**WEIGHT**

20lb

FELINE CARDIAC PARAMETERS	BODY WEIGHT	HR (BPM)	IVSd (cm)	LVIDd (cm)	LVWd (cm)	FS (%)	EF (%)
NORMAL PARAMETER	-----	150-240	0.3-0.6	1.0-2.1	0.25-0.6	35-67	80-100
PATIENT	20lb	NM	0.61	1.45	0.60	50	82
FELINE CARDIAC PARAMETERS	LA/AO M-Mode	LA/AO HEART BASE (Sisson)	LAD LA MAX 4 Chamber		LVOT VEL. (m/s)	RVOT VEL. (m/s)	IVRT (m/)
NORMAL PARAMETER	<1.5	1.6	0.7-1.7		<1.6	<1.3	40-60
PATIENT	1.3	1.4	1.3		1.0	1.3	--
Sisson D et al. JVIM 1991; 5: 232, Jacobs et al. Am J Vet Res 1985; 46:1705							

**Cardiac Presentation**

The echocardiogram in this patient demonstrated normal left atrial size based on 2 separate LA measurements. The cranial and caudal mitral valve leaflets presented normal linear structure and kinetics. No overt MR present on Doppler or SAM. The left ventricle presented borderline increased dimension, mild alinear contour and subjective mild ventricular remodeling. The myocardium presented normal echogenicity without subjective evidence of significant fibrotic or ischemic disease. The contractility of the ventricular walls was adequate and in normal range for this patient evidenced by the fractional shortening measurement and subjective evaluation of the different regions and angles of the myocardium. The left ventricular outflow tract demonstrated normal laminar flow and subjective structural integrity. Normal measured LVOT velocity was present. The right atrium and auricle revealed normal size, structure and content. No evidence of masses was noted or chamber overload. Tricuspid valvular assessment demonstrated adequate linear morphology and kinetics. No overt TR present on Doppler. The right ventricle was of normal size (1/3 diameter of LV), chordae structure, myocardial echogenicity and thickness. Pulmonic tract assessment revealed normal valve structure, laminar flow, and diameter (approx.1:1 pa/ao ratio). Normal measured RVOT velocity was present. No visible pericardial or free pleura fluid was noted or extra cardiac pathology in the visible planes. The cranial mediastinum and pericardial regions were free of masses in the visible window.

**ULTRASONOGRAPHIC FINDINGS**

**Primary**

**INTERPRETED BY**

R. McKenzie Daniel,  
 DVM, DABVP  
 (Canine and Feline)

**IMAGING PERFORMED BY**

Kelly Reschny

**HOSPITAL NAME**

Halton Peel Animal Hospital

**REFERRING VET**

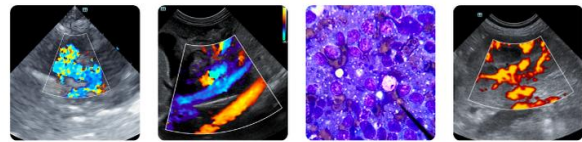
Walters

**INVOICE**

23576

**DATE**

01/16/2026



**PATIENT**

Keanu Marrcotte

- Borderline to static mild asymmetric LV hypertrophy, normal LV systolic function
- Normal LA
- Normal RA / RV

**SPECIES**

Feline

**BREED**

DSH

**SEX**

MN

**AGE**

8yr

**WEIGHT**

20lb

**INTERPRETED BY**

R. McKenzie Daniel,  
 DVM, DABVP  
 (Canine and Feline)

**IMAGING PERFORMED BY**

Kelly Reschny

**HOSPITAL NAME**  
 Halton Peel Animal  
 Hospital

**REFERRING VET**

Walters

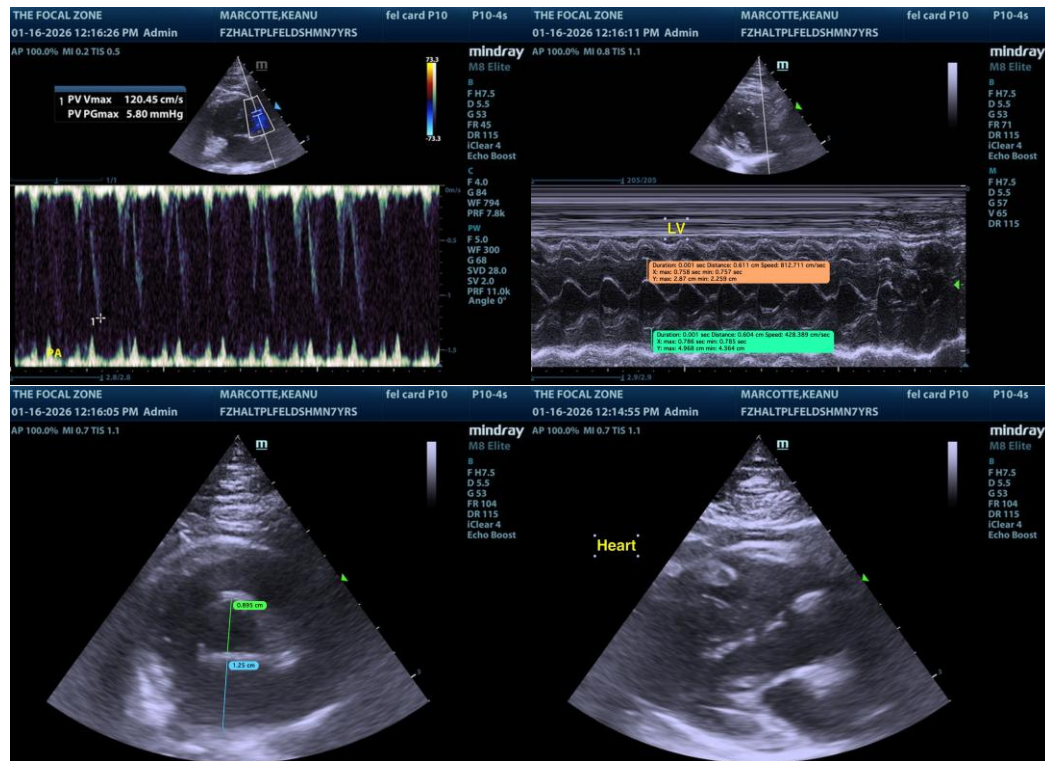
**INVOICE**  
 23576

**DATE**  
 01/16/2026

**INTERPRETATION OF THE FINDINGS & FURTHER RECOMMENDATIONS**

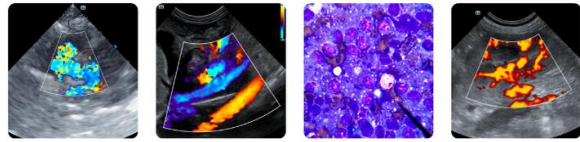
Similar cardiac presentation compared to previous studies without evidence of progression. A definitive cause of the murmur was not obvious with a benign flow murmur probable. Regardless, the continued lack of LA enlargement indicates the current and future risk of complication is low. No indication for cardiac medications. Continued monitoring at home for clinical signs and sonographic reassessment in 6 to 12 months is suggested.

Anesthetic risk is considered low to mild. The following protocol is suggested. Suggested anesthetic protocol may include opioid or Benzodiazepine pre-med, induction with Propofol or Alfaxalone, and appropriate gas anesthesia with avoidance of alpha 2 agonists.



The information and recommendations provided are based on the images presented by the referring veterinarian/sonographer. No evaluation can be communicated regarding pathology that was not visible in the image/video clips provided.

Thank you for this referral. If the clinical or image interpretation does not parallel your findings or if I



**PATIENT**

can be of any further assistance, please contact me.

Keanu Marrcotte

**R. McKenzie Daniel, DVM, DABVP (Canine/Feline Practice)**  
[info@sonopath.com](mailto:info@sonopath.com)

**SPECIES**

Feline

**BREED**

DSH

**SEX**

MN

**AGE**

8yr

**WEIGHT**

20lb

**INTERPRETED BY**

R. McKenzie Daniel,  
DVM, DABVP  
(Canine and Feline)

**IMAGING  
PERFORMED BY**

Kelly Reschny

**HOSPITAL NAME**

Halton Peel Animal  
Hospital

**REFERRING VET**

Walters

**INVOICE**

23576

**DATE**

01/16/2026